JOURNAL OF THE Selva Andina Animal Science
Official Journal of the Selva Andina Research Society.

Short Communication

ISSN 2311-3766 (print edition)
JSAAS
ISSN 2311-2581 (online edition)

Oxyclozanide in dairy cattle in the Cajamarca valley, as an alternative in the control of *Calicophoron microbothrioides*

Oxiclozanida en bovinos lecheros del valle de Cajamarca, como una alternativa en el control de *Calicophoron microbothrioides*

Rojas-Moncada Juan, Sotelo-Camacho Jorge, Torrel-Pajares Severino, Vargas-Rocha Luis*

Article Data

National University of Cajamarca.
Faculty of Veterinary Sciences.
Laboratory of Veterinary Parasitology.
Av. Atahualpa km 3, Cajamarca 06003.
Cajamarca, Peru.

***Contact address:**

National University of Cajamarca.
Faculty of Veterinary Sciences.
Laboratory of Veterinary Parasitology.
Av. Atahualpa km 3, Cajamarca 06003.
Cajamarca, Peru.

Luis Vargas-Rocha
E-mail address:
lvargasr17_1@unc.edu.pe

Keywords:

Antiparasitic,
feces,
eggs,
efficacy,
evaluation,
paramphistomosis,
cows.

***J. Selva Andina Anim. Sci.*
2022; 9(2):90-96.**
ID of article: 116/JSAAS/2022

Article history

Received July, 2022.
Returned September 2022
Accepted September, 2022.
Available online, October, 2022.

Edited by: Selva Andina Research Society

Palabras clave:

Antiparasitario,
heces,
huevos,
eficacia,
evaluación,
paramphistomosis,
vacas.

Abstract

The present investigation evaluates oxyclozanide's efficacy in controlling *Calicophoron microbothrioides* in dairy cows from a cattle farm in the Cajamarca valley. Fifteen Holstein Friesian cows naturally infected with *C. microbothrioides*, were orally administered oxyclozanide at a single therapeutic dose of 17 mg/kg live weight. Coproparasitological analyses were performed using the Fecal Egg Count Reduction Test at 10, 20 and 30 days after administration of the antiparasitic. The results show that oxyclozanide was effective at days 10 (100 %), 20 (98.96 %), and 30 (97.92 %). It is concluded that the evaluated antiparasitic caused a drastic reduction in the egg count, so it is considered an effective paranfistomicide in the control of *C. microbothrioides* in cattle of the evaluated farm.

2022. Journal of the Selva Andina Animal Science®. Bolivia. All rights reserved.

Resumen

La presente investigación evalúa la eficacia de oxiclozanida en el control de *Calicophoron microbothrioides* en vacas lecheras de un fundo pecuario en el valle de Cajamarca. Se utilizaron quince vacas Holstein frisona infectadas naturalmente con *C. microbothrioides*, se les administró oxiclozanida a dosis terapéutica única de 17 mg/kg de peso vivo, vía oral. Los análisis coproparasitológico mediante el Test de Reducción del Conteo de Huevos por gramo de heces, se realizaron a los días 10, 20 y 30 pos dosificación. Los resultados revelan que oxiclozanida fue eficaz en los días 10 (100 %), 20 (98.96 %) y 30 (97.92 %). Se concluye que, el antiparasitario evaluado ocasionó una drástica reducción en el conteo de huevos, por lo que se considera como un paranfistomicida eficaz en el control de *C. microbothrioides* en bovinos del fundo evaluado

2022. Journal of the Selva Andina Animal Science®. Bolivia. Todos los derechos reservados.

Introduction

Amphistomosis or paramphistomosis is a parasitosis caused by parasites of the Paramphistomidae family, heteroxenous trematodes of cosmopolitan distribution that affect ruminants, generating acute gastroenteritis, with high morbidity and mortality rates, particularly in young animals[1-5]. Immature parasites are located in the duodenum, abomasum, adults in the rumen and reticulum[6], they can even be located in the omasum[7]. Clinical signs are expressed in a variety of ways, including fetid diarrhea, profuse diarrhea, dehydration, polydipsia, hyporexia, emaciation, anorexia, cachexia, and even death[8,9].

In the valley of Cajamarca (Peru), *Calicophoron microbothrioides* has been identified as the causal agent of paramphistomosis in dairy cattle[10]. In one of the few studies carried out and published, a prevalence of 59±5 % of a total of 1508 cattle over one year of age, from 150 cattle farms in 19 hamlets was reported, concluding that the presence of this trematode was high and as a possible emerging disease[11]. In another study carried out in the Northern Cajamarca valley, the presence of *C. microbothrioides* was reported in 54.6 % of 377 dairy cows[12].

The use of chemical dewormers is the most common practice, carried out with the purpose of eliminating it, interfering in the parasite-host-environment interactions, mainly in the environment and contamination of pastures that allow the perpetuation of its biological cycle[13].

Oxyclozanide is considered one of the anthelmintics of choice against paramphistomids[6], However, in Cajamarca, there are few studies on the efficacy of active principles to combat this parasitosis, so the present investigation was carried out to evaluate the clinical efficacy of oxyclozanide at a single dose of 17 mg/kg live weight (BW) in Holstein Friesian cows from a cattle farm in the Cajamarca valley, naturally infected with *C. microbothrioides*.

Materials and methods

The present research was conducted during the months of March to April 2017, at the farm Tartar Pecuario and the Laboratorio de Parasitología Veterinaria, Facultad de Ciencias Veterinarias (LPV-FCV), both belonging to the Universidad Nacional de Cajamarca (UNC), located in the Cajamarca Valley, at an altitude of 2536 masl, with cold climate, average annual temperature 15.2 °C, annual rainfall 767.8 mm and average annual relative humidity 62.6 %[14].

The cows on this farm were not dosed with any type of antiparasitic for 12 weeks prior to the start of the study. Thus, a first coproparasitological sampling was carried out on all the animals of the farm (65 cows over 3 years of age) to identify naturally infected positive animals, thus forming a group of 15 Holstein Friesian cows with a parasite load greater than 1 egg per gram of feces (EPG). The animals were kept under similar rearing and feeding conditions (grazing), and fed with Ryegrass (*Lolium multiflorum*) and clover (*Trifolium repens*). EPG obtained on day 3 pre-dose (Day 0) was taken as a control, according to the protocol indicated by Ueno & Gonçalves[15].

For the calculation of the antiparasitic dose, the BW of the animals was estimated using a bovine weighing tape measure (synthetic tape for weighing zebu, Creole, dual purpose, and dairy cattle, given in kg, lb and @, in addition, it shows the animal's thoracic perimeter in cm and in). In the morning hours, after milking (6:00 to 7:00 a.m.), according to BW, oxyclozanide (Cerozanil® Oxyclozanide 15%, Biomont, Peru) was administered at a single dose of 17 mg/kg BW, orally. The identification of the cows was taken

from the earrings. Using veterinary obstetric gloves (disposable polyethylene gloves, ambidextrous, non-sterile, with a length of 86 cm and a thickness of 20 - 25 µm), approximately 100 g feces were collected directly from the rectum in the early morning hours, at day 10, 20 and 30 post dosage and processed using the natural sedimentation technique[16]. Finally, the antiparasitic efficacy was determined using the Fecal Egg Count Reduction Count Test (FERCT) and calculation of the efficacy percentage[15].

Results

Table 1 Administration of oxyclozanide (17 mg/kg BW, orally) in the control of *C. microbothrioides* in Holstein Friesian cows

Identification	n	Weight (kg)	Dosage (mL)*	EPG Day 0	EPG Post-dosing		
					Day 10	Day 20	Day 30
Ani		514.00	58.25	6.00	.00	.00	.00
Alicia		404.00	45.79	8.00	.00	.00	.00
Ana		575.00	65.17	4.00	.00	.00	.00
Elsi		420.00	47.60	2.00	.00	.00	.00
Oti		430.00	48.73	7.00	.00	.00 a	.00
Sol		530.00	60.07	9.00	.00	.00	.00
Dina		591.00	66.98	2.00	.00	.00	.00
Mayra	15	499.00	56.55	6.00	.00	1.00	1.00
Alga		529.00	59.95	7.00	.00	.00	.00
713		514.00	58.25	2.00	.00	.00	.00
Nora		416.00	47.15	15.00	.00	.00	.00
Ena		471.00	53.38	2.00	.00	.00	.00
Fiore		485.00	54.97	5.00	.00	.00	1.00
709		471.00	53.38	16.00	.00	.00	.00
Ada		591.00	66.98	5.00	.00	.00	.00
Total EPG				96.00	.00	1.00	2.00
Efficacy (%)					100.00	98.96	97.92

*Oxyclozanide 15%

Figure 1 Egg of *C. microbothrioides* under the microscope at 10X. Without dye (a) and with 5% parasitological Lugol (b)

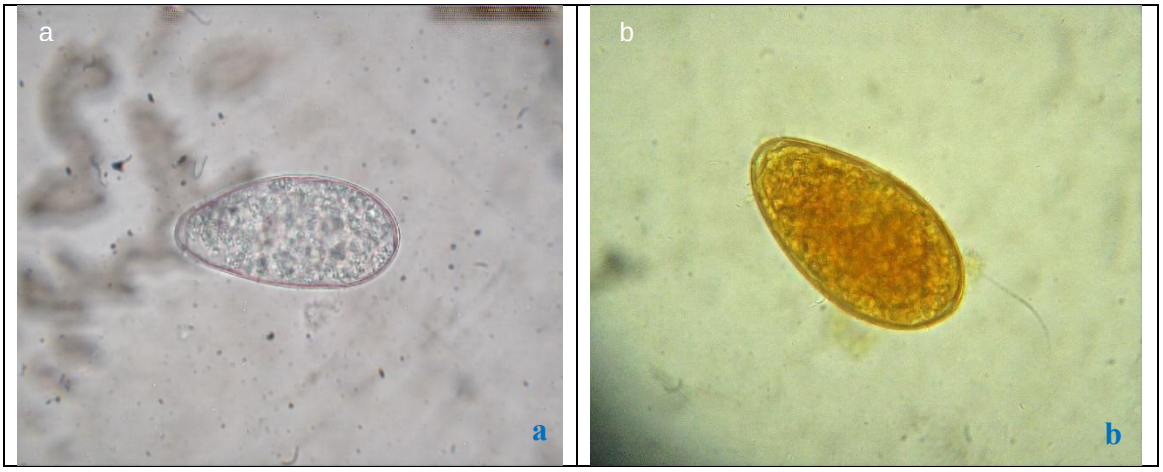

Discussion

Paramphistomes are the most important trematodes of the rumen and reticulum of ruminants[17], an important cause of loss of productivity due to the neglect of livestock farmers in recent times[18]. In Cajamarca, *C. microbothrioides* could be considered emerging, as has happened in Europe with other species of paramphistomes, a progressive increase in its prevalence, reports of acute cases in ruminants[3,19,20], preceded by globalization, climatic changes, importation of infected cattle, availability of more precise diagnostic techniques, relaxation of veterinary regulations in each country, continuous deworming with ineffective anthelmintics and the adaptation of the parasite to the intermediate host[5,21-23].

The results can only be contrasted locally, with a study conducted in dairy cattle in 2012, oxyclozanide was used (a commercial product not available in the current market), at a therapeutic dose of 12 mg/kg BW, and it resulted insufficiently active during the day 8 (37.13 %) and 16 (56.54 %)[24]. In a foreign study (Wales), oxyclozanide (18.7 mg/kg) associated with levamisole (9.4 mg/kg) significantly reduced the number of parasites in the small intestine, abomasum, and rumen reticulum in the control of immature paramphistomes in calves. With 2 doses administered 3 days apart, 100 % efficacy was obtained, with clinical improvement in affected calves[25]. In Galicia (Spain), oxyclozanide (15 mg/kg) also gave satisfactory results in Holstein cows, with HRCT values of 97-99 % and CPCR percentages (cattle positive by coprology reduction) of 85-93 %[26].

The clinical efficacy obtained resulted as the only alternative in the control of this trematode (100, 98.96, and 97.92 %) since the only commercial product available in the local market is oxyclozanide. Therefore, it represents a suitable alternative because macrocyclic lactones, benzimidazoles, niclosamide, resorantel, hexachlorophene, and closantel, gave limited or no effects in the treatment against paramphistomids[25,26-29].

In addition, it is necessary to clarify that in the animals dosed with oxyclozanide, diarrhea was aggravated for a period of 48 hours. A similar situation was observed in calves treated with oxyclozanide/levamisole, with the presence of transient diarrhea[25].

Although the animals were not subjected to special management and feeding conditions, they were kept grazing in the same paddocks, taking for granted their possible reinfection, which was evaluated until day 30 (4 weeks), since the prepatent period of *C. microbothrioides* ranges from 7 to 10 weeks[7]. Therefore, it is necessary to work on integrated control systems for this parasitosis, since the search for new active principles involves years of study, prioritizing effective control methods, with measures that are adapted and include pasture and animal management, delimiting intermediate host habitats, avoiding irrigation by immersion, rotational grazing and using efficient medications that are available[9,30]. One of the major sources of infection is green forages. In one study it was reported that the contamination rate of fresh forages with eggs and metacercariae was higher in dry forages, 58.77 and 26.1 %, respectively[1].

It is concluded that oxyclozanide at a single dose of 17 mg/kg BW, orally, is effective (> 97 % efficacy) in the control of *C. microbothrioides* in dairy cattle of the evaluated farm. The success obtained could be of interest to be implemented in a cost-effective treatment, since it provides optimal results with a single administration, in extensive cattle breeding, avoiding greater stress to the cattle and less time in its execution by the working personnel.

Source of financing

The research was funded by the same authors.

Conflicts of interest

The authors declare that they have no conflicts of interest affecting this research.

Acknowledgments

The authors would like to thank the Facultad de Ciencias Veterinarias from the Universidad Nacional de Cajamarca, Peru, for providing the animals and the means to carry out this study.

Ethical considerations

All procedures were aligned with the Ley de protección y bienestar animal del Estado peruano (Ley N° 30407).

Authors' contribution to the article

Juan Rojas Moncada, *Jorge Sotelo Camacho*, and *Severino Torrel Pajares* conceptualized, designed the methodology, supervised, and directed the research. *Luis Vargas Rocha* contributed to the software, validation, data curation, writing, preparation of the original drafts, visualization, drafting-revising, and editing of the manuscript. All authors approved the final manuscript.

Research limitations

Comparative evaluation of efficacy by necropsy of the animals under study, in addition to a reduced sample size.

Literature cited

1. González-Warleta M, Lladosa S, Castro-Hermida JA, Martínez-Ibeas AM, Conesa D, Muñoz F, et al. Bovine paramphistomosis in Galicia (Spain): prevalence, intensity, aetiology and geospatial distribution of the infection. Vet Parasitol 2013;191 (3-4):252-63. DOI: https://doi.org/10.1016/j.vetpar.2012.09.006
2. Hajipour N, Mirshekar F, Hajibemani A, Ghorani M. Prevalence and risk factors associated with amphistome parasites in cattle in Iran. Vet Med Sci 2021;7(1):105-11. DOI: https://doi.org/10.1002/vms3.330
3. Huson KM, Oliver NAM, Robinson MW. Paramphistomosis of ruminants: An emerging parasitic disease in Europe. Trends Parasitol 2017;33(11): 836-44. DOI: https://doi.org/10.1016/j.pt.2017.07.002
4. Khedri J, Radfar MH, Borji H, Mirzaei M. Prevalence and intensity of *Paramphistomum* spp. in cattle from South-Eastern Iran. Iran J Parasitol 2015;10(2):268-72.
5. Zintl A, Garcia-Campos A, Truddgett A, Chryssafidis AL, Talavera-Arce S, Fu Y, et al. Bovine paramphistomes in Ireland. Vet Parasitol 2014; 204(3-4):199-208. DOI: https://doi.org/10.1016/j.vetpar.2014.05.024
6. Urquhart GM, Armour J, Duncan JL, Dunn AM, Jennings FW. Parasitología Veterinaria. 2ª Ed. Zaragoza: Acribia S.A; 2001. p. 130-2.
7. Torrel TS, Paz A. Paramphistomosis en bovinos y ovinos en Cajamarca. 1ª ed. Cajamarca: Martínez Compañón Editores S.R.L.; 2015. p. 109.
8. Horak IG. Paramphistomiasis of domestic ruminants. Adv Parasitol. 1971;9:33-72. DOI: https://doi.org/10.1016/s0065-308x(08)60159-1
9. Rolfe PF, Boray JC, Nichols P, Collins GH. Epidemiology of paramphistomosis in cattle. Int J Parasitol 1991;21(7):813-9. DOI: https://doi.org/10.1016/0020-7519(91)90150-6
10. Manrique A, Sanabria REF, Cabrera M, Ortiz P. Molecular identification of Paramphistomes from

cattle in Cajamarca, Peru. In: 24th International Conference of the World Association for the Advancement of Veterinary Parasitology. Australia: Perth; 2013.

11. Torrel T, Rojas J, Vera Y, Huamán O, Plasencia O, Oblitas I. Prevalencia de paranfistomidosis y fasciolosis en ganado bovino lechero del valle de Cajamarca, Perú. En: XXIV Reunión de la Asociación Latinoamericana de Producción Animal: XL Congreso de la Sociedad Chilena de Producción Animal, A.G.: Puerto Varas 9-13 noviembre de 2015, Chile; 2015. p. 315-16.
12. Cusquisiban N. Tremátodos en el ganado vacuno en la zona norte del Valle de Cajamarca 2014 [tesis licenciatura]. [Cajamarca]: Universidad Nacional de Cajamarca; 2014.
13. Sintayehu M, Mekonnen A. Prevalence and intensity of paramphistomum in ruminants slaughtered at Debre Zeit industrial abattoir, Ethiopia. Glob Vet 2012;8(3):315-9.
14. Servicio Nacional de Meteorología e Hidrología del Perú [Internet]. Lima: Plataforma digital única del Estado Peruano; 2018 [citado 03 de diciembre de 2019]. Recuperado a partir de: https://www.gob.pe/senamhi
15. Ueno H, Gonçalves P. Manual para el diagnóstico de los helmintos de Rumiantes. 4ª ed. Tokio: Japan International Cooperation Agency (JICA): 1998. p. 130-131.
16. Fiel CA, Steffan PE, Ferreyra DA. Técnica de sedimentación para el diagnóstico coprológico de *Fasciola hepatica*. En: Fiel CA, Steffan PE, Ferreyra DA, editors. Diagnóstico de las parasitosis más frecuentes de los rumiantes: técnicas de diagnóstico e interpretación de resultados. 1ra ed. Buenos Aires: Abad Benjamín; 2011. p. 100-6.
17. Tehrani A, Javanbakht J, Khani F, Hassan MA, Khadivar F, Dadashi F, et al. Prevalence and pathological study of Paramphistomum infection in the small intestine of slaughtered ovine. J Parasit Dis 2015;39(1):100-6. DOI: https://doi.org/10.1007/s12639-013-0287-4
18. Anuracpreeda P, Wanichanon C, Sobhon P. *Paramphistomum cervi*: antigenic profile of adults as recognized by infected cattle sera. Exp Parasitol 2008;118(2):203-7. DOI: https://doi.org/10.1016/j.exppara.2007.08.005
19. Alzieu PJP, Dorchies P. Reemergence of cattle paramphistomiasis in France: Current review of epidemiology, pathophysiology and diagnosis. Bull Acad Vét France 2007;160(2):93-9. DOI: https://doi.org/10.4267/2042/47872
20. Jones RA, Brophy PM, Mitchell ES, Williams HW. Rumen fluke (*Calicophoron daubneyi*) on Welsh farms: prevalence, risk factors and observations on co-infection with *Fasciola hepatica*. Parasitology 2017;144(2):237-47. DOI: https://doi.org/10.1017/S0031182016001797
21. Iglesias-Piñeiro J, González-Warleta M, Castro-Hermida JA, Córdoba M, González-Lanza C, Manga-González Y, et al. Transmission of *Calicophoron daubneyi* and *Fasciola hepatica* in Galicia (Spain): Temporal follow-up in the intermediate and definitive hosts. Parasit Vectors 2016;9(1):610. DOI: https://doi.org/10.1186/s13071-016-1892-8
22. Jones RA, Williams HW, Dalesman S, Brophy PM. Confirmation of *Galba truncatula* as an intermediate host snail for *Calicophoron daubneyi* in Great Britain, with evidence of alternative snail species hosting *Fasciola hepatica*. Parasit Vectors 2015;8:656. DOI: https://doi.org/10.1186/s13071-015-1271-x
23. Mage C, Bourgne H, Toullieu JM, Rondelaud D, Dreyfuss G. *Fasciola hepatica* and *Paramphistomum daubneyi*: changes in prevalences of natural infections in cattle and in *Lymnaea truncatula* from central France over the past 12 years. Vet

Res 2002;33(5):439-47. DOI: https://doi.org/10.1051/vetres:2002030

24. Escalante L, Torrel S. Eficacia de la Oxiclozanida al 3.4 % a los 8 y 16 días post dosificación en el control de la infección causada por paramphistomidos en el ganado vacuno [tesis licenciatura]. [Cajamarca]: Universidad Nacional de Cajamarca; 2012.
25. Rolfe PF, Boray JC. Chemotherapy of paramphistomosis in cattle. Aust Vet J 1987; 64(11): 328-332. DOI: https://doi.org/10.1111/j.1751-0813.1987.tb06060.x
26. Arias MS, Sanchís J, Francisco I, Francisco R, Piñeiro P, Cazapal-Monteiro C, et al. The efficacy of four anthelmintics against *Calicophoron daubneyi* in naturally infected dairy cattle. Vet Parasitol 2013;197(1-2):126-9. DOI: https://doi.org/10.1016/j.vetpar.2013.06.011
27. Rolfe P, Boray J. Comparative efficacy of moxidectin, an ivermectin/clorsulon combination and closantel against immature paramphistomes in cattle. Aust Vet J 1993;70(7):265-6. DOI: https://doi.org/10.1111/j.1751-0813.1993.tb08047.x
28. Malrait K, Verschave S, Skuce P, Van Loo H, Vercruysse J, Charlier J. Novel insights into the pathogenic importance, diagnosis and treatment of the rumen fluke (*Calicophoron daubneyi*) in cattle. Vet Parasitol 2015;207(1-2):134-9. DOI: https://doi.org/10.1016/j.vetpar.2014.10.033
29. García-Dios D, Díaz P, Viña M, Remesar S, Prieto A, López-Lorenzo G, et al. Efficacy of Oxyclozanide and Closantel against rumen flukes (Paramphistomidae) in naturally infected sheep. Animals (Basel) 2020;10(11):1943. DOI: https://doi.org/10.3390/ani10111943
30. Morley FHW, Donald AD. Farm management and systems of helminth control. Vet Parasitol 1980;6(1-3):105-34. DOI: https://doi.org/10.1016/0304-4017(80)90040-0

Editor's Note:
***Journal of the Selva Andina Animal Science* (*JSAAS*). All statements expressed in this article are solely those of the authors and do not necessarily represent those of their affiliated organizations, or those of the publisher, editors and reviewers. Any product that may be evaluated in this article, or claim that may be made by its manufacturer, is not guaranteed or endorsed by the publisher.**